

# Embryo Sexing

*K.Sahayaraj*

# INTRODUCTION

- Preselection of sex
- Earlier approaches superstition based
- Modern techniques make it possible now
- Either X-Y sperm sorting or Embryo sexing

# RELEVANCE

- Many constrains against prenatal sex determination
- In animal science the technology can be a great boon
- Progressive & rich dairy farmers are now willing to spend money for new technologies to improve profitability of their herd

# SEX DETERMINATION IN EMBRYO

- ◆ Sex determined in pre-implantation embryos
- ◆ Approach- either invasive or non invasive
- ◆ Splitting of sexed embryos
- ◆ First successful embryo sexing done by Gardner, 1968 in rabbits by cytological method (Barr body observation)

# VARIOUS METHODS OF EMBRYO SEXING

## ■ Non invasive Methods--

- Immunological assay of HY antigen
- Quantification of X-linked enzyme

*William et al., 1986*

- Differential growth of male & female embryo

*Yadav et al., 1992*

## ■ Invasive Methods--

- Cytogenetic analysis
  - observing Barr bodies
  - chromosome analysis
- Y-specific DNA probe
- Y-specific DNA primer & PCR

# BARR BODY OBSERVATION

Gardner, 1968

- Barr body forms after certain stage in embryo depending on species
- Performed at blastocyst stage
- Affected normal embryonic development in some case
- outdated now
- Not applicable in domestic species

King W A., 1984

# CHROMOSOME ANALYSIS

- k Sexing from Trophoblast biopsy, day 12 -- 15
- k Accuracy 58.5--68% Hare *et al.*, 1976
- k Mustafa, (1978), sexed embryo at 6-7 days but low efficiency & low survival rate reported
- k Sharma A. *et al.*(1987) reported 57% efficiency by this technique
- k Slides prepared at metaphase stage
- k Depends on how many cells at metaphase stage
- k Takes an expert 5 hours to process 12 - 15 embryo

# DETECTION OF H-Y ANTIGEN

**D**H-Y detection used for murine,bovine,porcine embryo.

**D**Detection as early as 8 cell stage.

**D**Can have two approaches cytotoxic or immunofluorescent.

*White et al., 1982*

**D**In pigs detected only after removal of zona pellucida.

**D**Accuracy 84%cattle,85%goat,81%pigs.

*G.B.Anderson, 1987*



# Immunofluorescent Assay

- /// Poor quality embryo show fluorescence unrelated to presence of antigen
- /// detection stage specific
- /// Monoclonal and polyclonal antibodies has equal effect

Hossipian V.F.M., 1993

# ENZYME ACTIVITY DETECTION

- ❖ In male and female different no. of X in initial stages
- ❖ Different amount of enzymes produced
- ❖ William 1986, reported activity of G-6PD in whole embryo; accuracy was 64%
- ❖ Monk & Handyside measured activity of HPRT & expressed activity as a ratio of autosomal encoded APRT
- ❖ reported accuracy of 95%

# USE OF DNA PROBES

Bondioli *et al.*, 1989


- ◆ Y-specific probe used for sexing bovine blastocyst (6--8 days)
- ◆ High accuracy
- ◆ Minimum time required to conduct assay is 10 days

# USE OF PCR

- ◆ Revolutionized the technique of embryo sexing
- ◆ Reduced time requirement
- ◆ Increased efficiency
- ◆ Embryos have been successfully sexed in a number of farm animals by using this technique

# EMBRYO SEXING TECHNIQUE

(a)



Remove oocytes following superovulation

Fertilize in vitro

(b)



Culture in vitro to 6- to 10-cell stage

# Technique

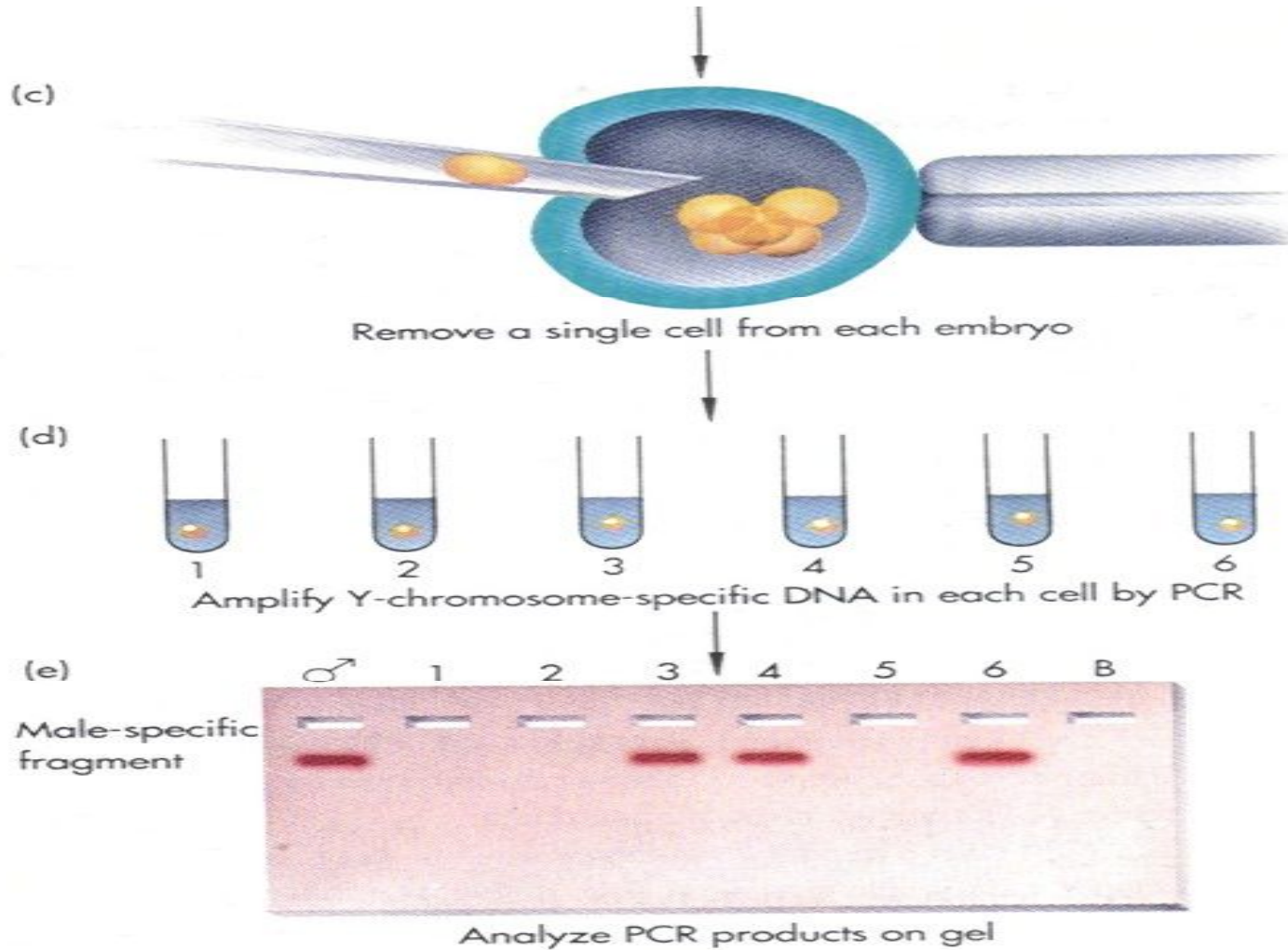
The sexing technique is based on the chromosomal difference that exists between embryos of different sex, that is on the presence or absence of the Y chromosome (the male embryos carry the Y chromosome while the female embryos do not).

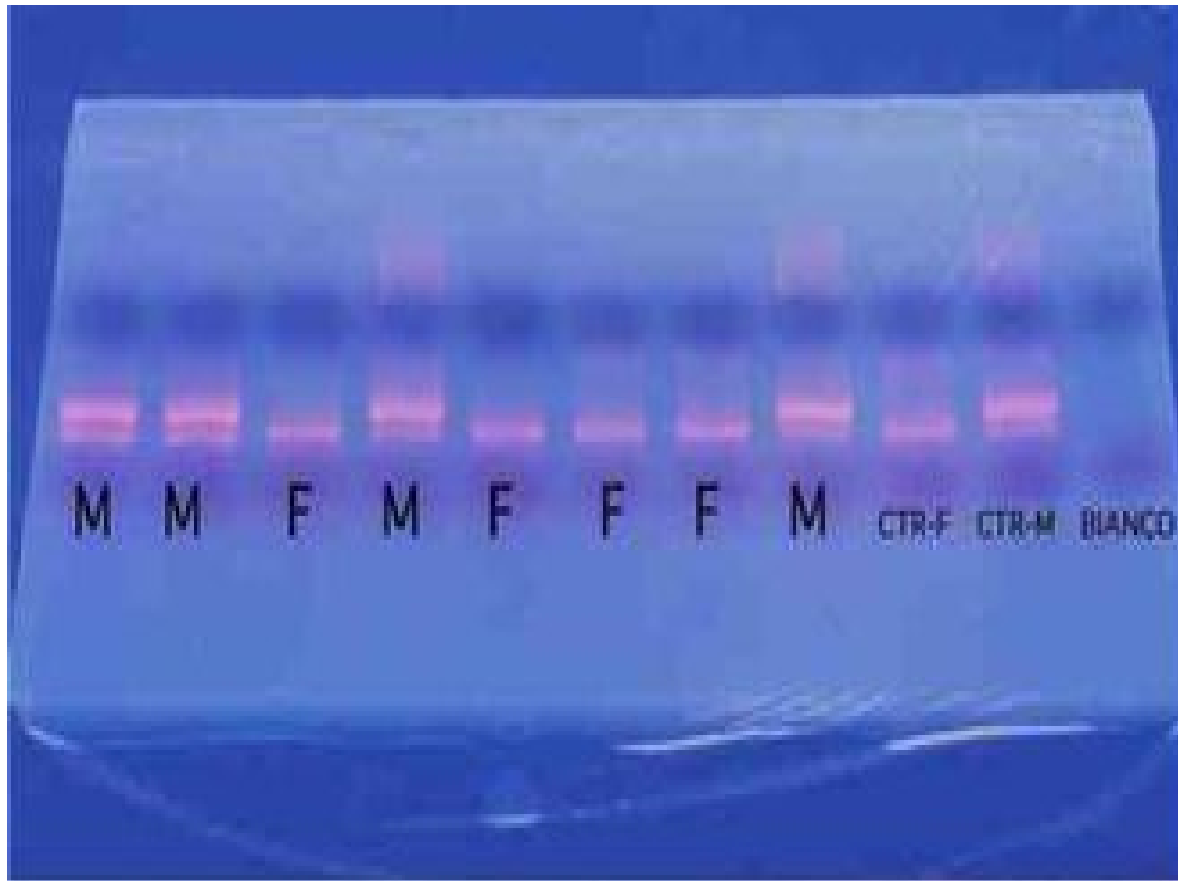
In order to highlight this difference a small group of cells of the embryo is removed by using a microblade (Fig.1).

The DNA contained in these cells is amplified with a procedure called PCR (Polymerase Chain Reaction) that allows to find out the presence or absence of the male chromosome Y.

Together with the signal for the Y chromosome a second signal of control is obtained for all samples analysed independently of sex.

# CONTD...







# Cont...

- These signals are visible as fluorescent bands after electrophoresis of the DNA samples in an agarose gel.
- The interpretation of the result is very simple: the presence of a single band indicates that the biopsy has been taken from a female embryo while the presence of two bands indicates that the biopsy has been taken from a male embryo.
- The sexing procedure is accurate at 97%. The sexed embryos can be successfully frozen exactly as the non sexed embryos.
- The embryo sexing
- The embryo sexing service started in 1997; since then over 2000 LTR embryos have been sexed. This service is available also for embryos produced on field.

# BASIC PROCEDURE OF EMBRYO SEXING

- Collection of embryos produced in vitro or in vivo
- ↓
- Selection of grade one or grade two embryos
- ↓
- Embryo washed with PBS & placed in a drop containing 200 mM sucrose under micromanipulator
- ↓
- Zona pellucida cut open with fine micro blade
- ↓
- Few blastomere sucked with fine aspiration pipette
- ↓
- Washed in KCl & transferred to Eppendorf tube

# ISOLATION OF EMBRYONIC DNA

- Biopsy in 0.5 ml Eppendorf tube + Proteinase-K + 9  $\mu$ L of lysis buffer
- ↓
- Overlaid with 25  $\mu$ L of mineral oil
- ↓
- Incubated at 37° C for 10- 60 min
- ↓
- Inactivation of proteinase-K at 98 ° C for 10 min.
- ↓
- Cooled at 4 ° C

# AMPLIFICATION OF DNA

- Ø 15  $\mu\text{L}$  of PCR reaction mixture(PCR reaction buffer, primers, 1.5  $\mu\text{L}$  of Taq DNA polymerase & 125  $\mu\text{g}$  of Ethidium bromide) is added to the tube
- Ø Subjected to PCR cycling
- Ø 3 min. denaturation at 94 ° C • 10 cycles of denaturation at 92 ° C • Annealing at 50 ° C (80 seconds) • Extension at 72 ° C for 20 seconds
  - Further 40 cycles at 60 ° C of annealing temperature
  - Final extension achieved by 5 min. incubation at 72 ° C

# IDENTIFICATION OF SEX

- ✓ It can be done by two approaches--
  - i) **Electrophoretic method**-- In PCR second pair of primer added to increase accuracy  
After electrophoresis Y-specific bands are observed  
Autosomal primer commonly used is C1C2
  - ii) **Direct observation under UV light**--  
tubes having male DNA show bright pink fluorescence  
Hasler *et al.*, 2002 sexed embryos within 2 hours.

# CURRENT STATUS

- Embryo sexing done for cattle, sheep, pigs, horses, goats, buffalo & humped cattle

*Apparao et al., 1992*

- Differential growth rate not applicable to choose embryos

*Evanova et al., 1997*

- Single cell is sufficient for sexing

*Chrenek et al., 2000*

- Rapid sexing within 2 hours by using multiplex PCR they used BOV-97M & bovine 1.715 satellite DNA sequence

*PARK et al., 2001*

- Non Electrophoretic method for PCR sexing reduced time requirement to less than 2 hours

*Hasaler et al., 2002*

## CONTD..

- New techniques *viz.* nested PCR & LAMP  
(loop mediated isothermal amplification)

Hirayama *et al.*, 2003

- Hyperglycemia induced apoptosis

Jimenez *et al.*, 2003

# USES OF EMBRYO SEXING

- + Altering the male & female sex ratio in farm animals
- + Increase in milk & meat production
- + Control of incidence of freemartinism
- + Getting quality bulls for P.T. programs
- + Conservation of rare breeds of farm animals



# NECESSITY IN INDIAN CONDITION

- Primarily agricultural economy with animal husbandry contributing 11% to GDP
- Shortage of fodder for milch animals with excess males consuming major portion

# CONSTRAINTS

- " Poor infrastructure facilities
- " Low level of education & training
- " High cost of the technology
- " Difference between research & field conditions
- " Less availability of indigenous technology & materials
- " Lack of 3 D's

# WE SHALL OVERCOME

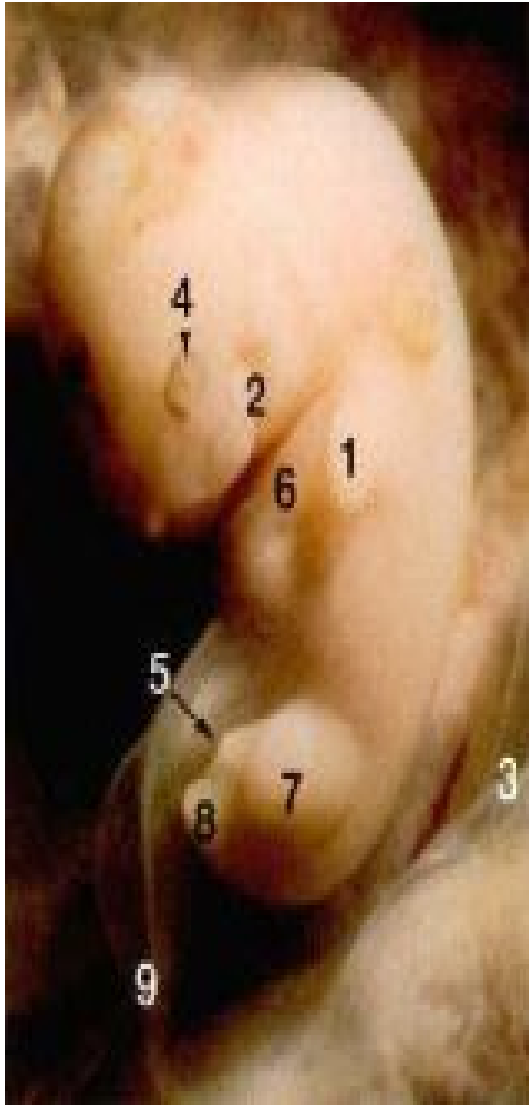
- ✦ Great progress in scientific fields in spite of constraints
- ✦ As time advances technology becomes more affordable

# SUGGESTED STRATEGY

- 🔑 Technicians at research institutes master the methodology
- 🔑 Perform in presence of field workers
- 🔑 In second stage infrastructure set up at local places
- 🔑 Finally, mobile laboratories are set up
- 🔑 Constant monitoring & guidance by research workers
- 🔑 Use of indigenous products

# Scanning

## 6 week old embryo

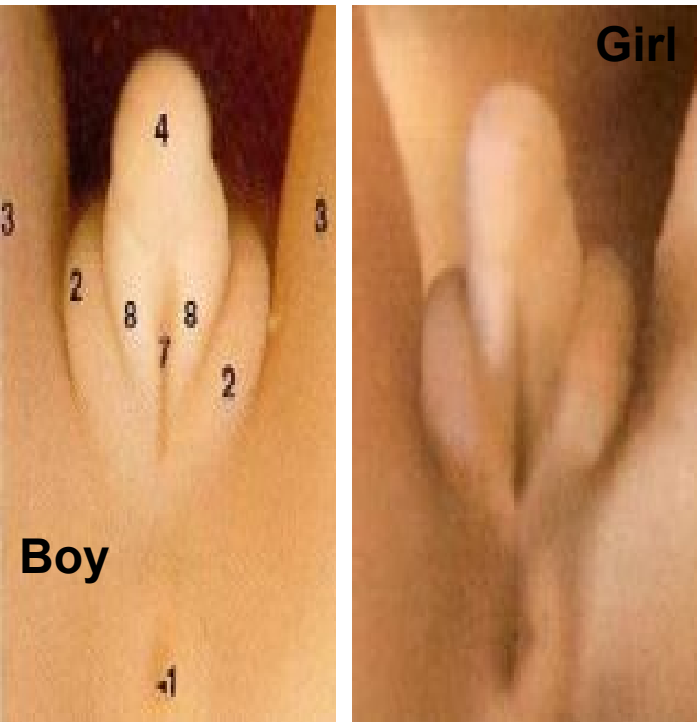


At the sixth week the site of the genitals is a small bud, called the genital tubercle.

Until the ninth week of fetus development, the embryonic reproductive apparatus is the same one for the two sexes.

Buds of the arm, Arc branchial, Placenta membrane, Eye, **Genital tubercle**, Site of the heart, Bud of the leg, Tail and Umbilical cord

## 9 week old embryo - 11 weeks Pregnant

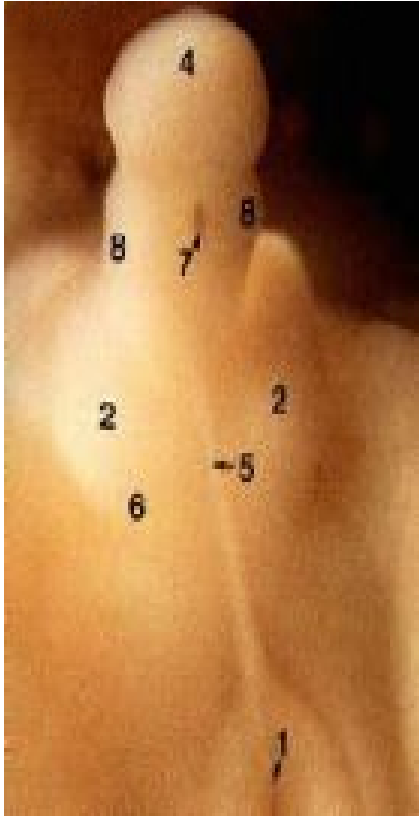


At the ninth week, there are not yet any notable differences.

The boy is on the left and the girl on the right. You find the same structures on both fetus.

1. Anus
2. Labioscrotal folds
3. Legs
4. Genital tubercle
7. Urethral groove
8. Urogenital folds

## Male - 11 week old fetus - 13 weeks Pregnant



( Fetus size = 2.5 inch, 64 mm )

With a boy, the genital tuber will form the glans penis (4). The body of the penis will be formed by the fusion of the urogenital folds, this fusion is not yet completely finished (7). The scrotum (6) is formed by the fusion of the labioscrotal folds (2). The Raphe [line] of the scrotum (5) corresponds to the zone of fusion of the labioscrotal folds.

At this stage of development, the testicles are located in the abdomen. They will not go down into the scrotum (6) until about the seventh or eighth month of pregnancy.

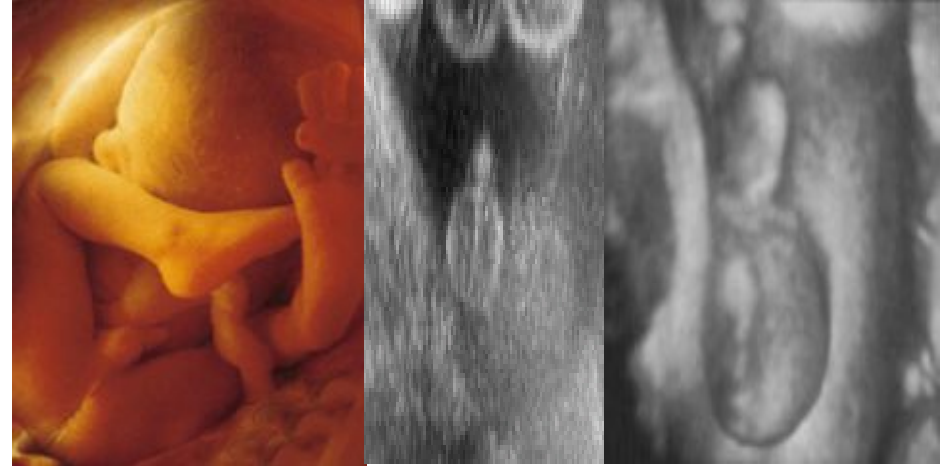The foreskin is formed in the twelfth week of development.



## Female changes

In the absence of the SRY gene, of the Y chromosome, a female embryo will develop.

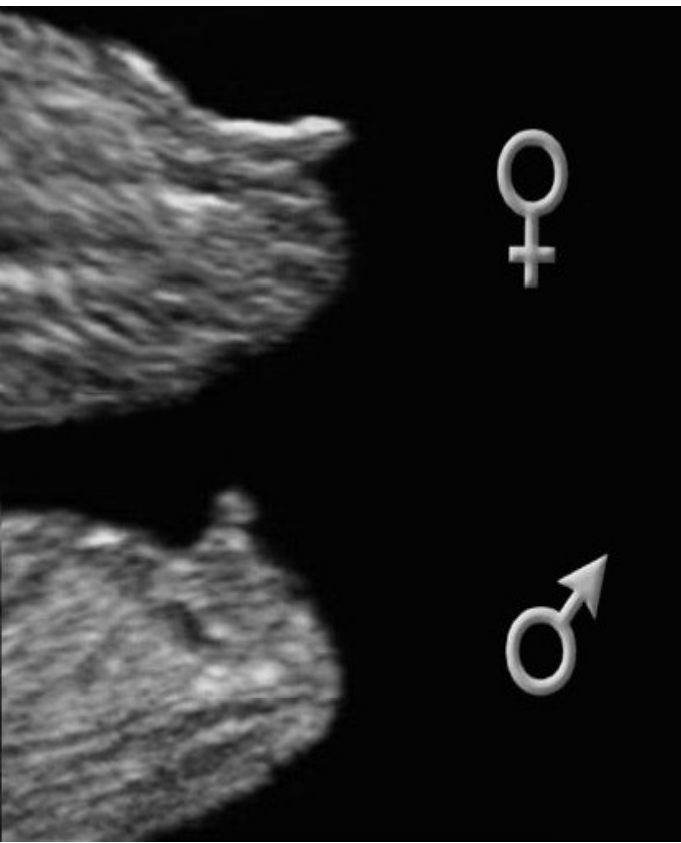
The development of the female external genitalia is promoted by the presence of estrogen and other hormones within the maternal system.



**At around 12 weeks a sonographer may make a 'best guess' as to the gender of baby from a scan, but this can, and will be, only a little better than 50/50.**

The correct visualization of any fetal part depends on many factors such as fetal position, amount of amniotic fluid and thickness of the abdominal wall.

The following images are not typical, as intermediate forms exist, establishing gender can sometimes be very difficult.



**Angle of the dangle**

With the male fetus, the genital tubercle usually creates an angle of greater than 30° with the lower part of the spine.

In the female fetuses, the genital tubercle protrudes in the same direction as the lower portion of the spine with an angle of less than 30° relative to the backbone.